FINAL REPORT

Title: Visual Anatomic Guidance to Facilitate Ultrasound Image Acquisition

NAG9-#: 1258

NASA Solicitation: 99-HEDS-03-252

PI Name: Florence H. Sheehan, M.D.

PI Address: University of Washington Box 356422, Seattle, WA 98195-6422

PI Phone: (206) 543-4535

PI Fax: (206) 685-9394

PI Email: sheehan@u.washington.edu

Co-Investigator(s): none **Affiliation(s)**: N/A

Introduction

We developed a visual anatomic guidance system to help flight personnel acquire medical ultrasound images that are correctly positioned anatomically in the standard views. The guidance system displays the location of the current image plane relative to the anatomy of the target organ. This anatomic information is provided in a real-time graphic display that the sonographer can monitor in addition to the ultrasound screen while manipulating the ultrasound transducer. The rationale for this system is to improve the diagnostic accuracy of medical ultrasound performed by flight crew. The **hypothesis** was that 1) even persons not trained as sonographers can acquire more accurately positioned images with real-time guidance than without, and 2) guidance will improve accuracy and reproducibility in quantitative analysis of ultrasound images.

The **specific aims** were to:

1. Develop three methods for visual anatomic guidance, and compare their performance on imaging the left ventricle of the heart. Note that although the target organ in the present proposal was the heart, the guidance system can be applied to other organs as well.
2. Test a prototype system for tracking the location and orientation of the ultrasound transducer that offers immunity to ambient ferromagnetic interference, a feature that reduces restrictions on where it can be used.
3. Widen the applicability of this technology on Earth by applying guidance to imaging the right ventricle.

By providing technology to improve medical diagnosis and monitoring of health status, this research directly addresses Critical Path roadmap questions #11.03, 11.12, 11.22, 11.26, 11.30, and 11.38. In addition, the results of this research provide a capability that may assist ultrasound-based therapeutic interventions, addressing questions # 11.02 and 11.12.

Background: Ultrasound is an ideal modality for medical imaging in Space because it is portable, compact, battery-powered, risk-free, and inexpensive. The disadvantage of ultrasound is its reliance on operator skill in acquiring images of diagnostic quality. Ultrasound image acquisition requires not only extensive training but also continuing practice. The acquisition of poor quality ultrasound images confounds diagnosis and medical management. Optimal imaging is also important for the effective use of ultrasound for therapy.

Materials and Methods

#1: Visual Anatomic Guidance System

We developed the computer software to implement all three methods of visual anatomic guidance. The *line of intersection* (Fig.1) displays the current image plane's location as a line drawn on each of two "scout" images, a short axis view and a long axis view, recorded at the beginning of the study. The disadvantage of this approach is that it does not indicate whether the current image plane is tilted inappropriately in the 3rd or out-of-plane dimension unless two scout images are monitored.

The *intersecting planes* (Fig. 1) method displays the scout images in three-dimensional (3D) space with the current image overlaid in semi transparent mode. The 3D presentation provides more anatomic assistance in image plane positioning because it shows not only the position but also the

orientation of the current image relative to the heart as revealed in the selected scout image(s). By visualizing the intersecting image planes directly, one can appreciate very quickly whether they intersect each other at 90°, lie perpendicular to the left ventricular wall, and pass through the apex and other anatomical landmarks.

Visualizing the image plane's *intersection with the 3D target surface*, the third method that we had proposed, helps the sonographer understand not only where the current image plane is located, but also where it should be to cut a short axis or long axis view. The current image does not compete with the scout image for visibility. Instead its position and orientation relative to the heart are clearly visible (Fig. 2). The difficulty of this approach is the need to prepare a 3D surface reconstruction of the patient's heart rapidly to serve as the anatomic guide for further imaging. However we at the University of Washington had previously developed a method to do rapid surface fitting by estimating the 3D surface of the target organ from as few as four input data points. The method utilizes prior information about the organ's shape and shape variations to assist in surface estimation. This knowledge base is embodied in a catalog of 3D reconstructions of the organ's surface from patients with diverse diagnoses. We fit the input data points to a weighted average of LV shapes in the catalog to generate the estimated surface. We call this method SmartFit. An advantage is that the SmartFit method consistently produces a ventricle-like shape.

We tested the impact of visual guidance on the accuracy and reproducibility of quantitative analysis. We compared the accuracy of left ventricular volume determination from images acquired with vs. without anatomic guidance in patients and normal subjects. In this test, the subjects were imaged lying in the left lateral position in held end-expiration using a commercial ultrasound machine (HDI-3000, ATL, Bothell, WA). The position and orientation of the images was tracked using a magnetic field system (Flock of Birds™, Ascension Technology, Burlington, VT) (Fig. 4). The true volume was that computed from a 3D scan, which is acquired over five to six 6-10 sec scans (1, 2). The end diastolic and end systolic images were selected and the borders of the LV and other anatomic features were traced. The border points were fitted with a spline curve and converted to x, y, z coordinates using probe position and orientation data. A triangulated mesh reconstruction was generated from the traced borders using the piecewise smooth subdivision surface method. The true volume was compared with two-dimensional (2D) volumes computed from two long axis views using Simpson's method.

Although not originally an aim of this project, we also tested the effect of guidance on measuring right ventricular volume. The true volume again was that measured from a 3D scan and reconstruction from manual border tracing. 2D right ventricular volume was computed by two methods. In the monoplane ellipsoidal approximation method (3), in which all measurements are taken from the apical four chamber view. The second 2D method was a modification of the biplane pyramidal approximation method (4). As originally described, an area is measured from the four-chamber view and the long axis length from a subcostal view. However since we are unable to change the subject's position during guidance or during 3D scanning, as would be required for the subcostal view, we computed the long axis length from the right ventricular apex and pulmonary valve as visualized in the images required for the 3D target surface method of visual guidance. We compared the true right ventricular volume with the two 2D volumes, and also with the volume of the catalog fit surface generated for guidance.

Aim #2: Tracking the Ultrasound Transducer:

The second aim was to test a prototype magnetic field tracking system developed by Internav, Inc. This vendor offered a tracking system immune to local interference from below the patient. Using an *in vitro* system (Fig. 5), we measured the root mean square (RMS) uncertainty in repeatedly locating a point target in space. Specifically, we mounted the tracking system's receiver on a stylus with a ball tip that we used to locate two sockets positioned 10 cm apart on a

Plexiglas box. We then measured the system's precision in repeatedly locating each socket at baseline (without ferromagnetic interference), and on top of a hospital stretcher such as used for echocardiography.

Aim #3: Visual Guidance for the Right Ventricle

To widen the applicability of visual guidance technology in clinical practice on Earth, our third aim was to validate the accuracy of our piecewise smooth subdivision surface reconstruction method for determining the shape and volume of the right ventricle, and to apply guidance to imaging the right ventricle. Due to overlap between grants and the 10% cut in our NASA grant budget, the validation was performed under other funding.

We performed 3D echo imaging of animal hearts in a water bath, and compared the volume and mass obtained from analyzing the images with the true values measured from the hearts. To validate the ability of our reconstruction method to accurately represent the 3D shape of an organ, we also prepared plaster casts of the right ventricular endocardium, laser scanned the casts, and compared the 3D surface reconstructed from the dense, accurate, laser scan data to the 3D surface reconstructed from the echo images.

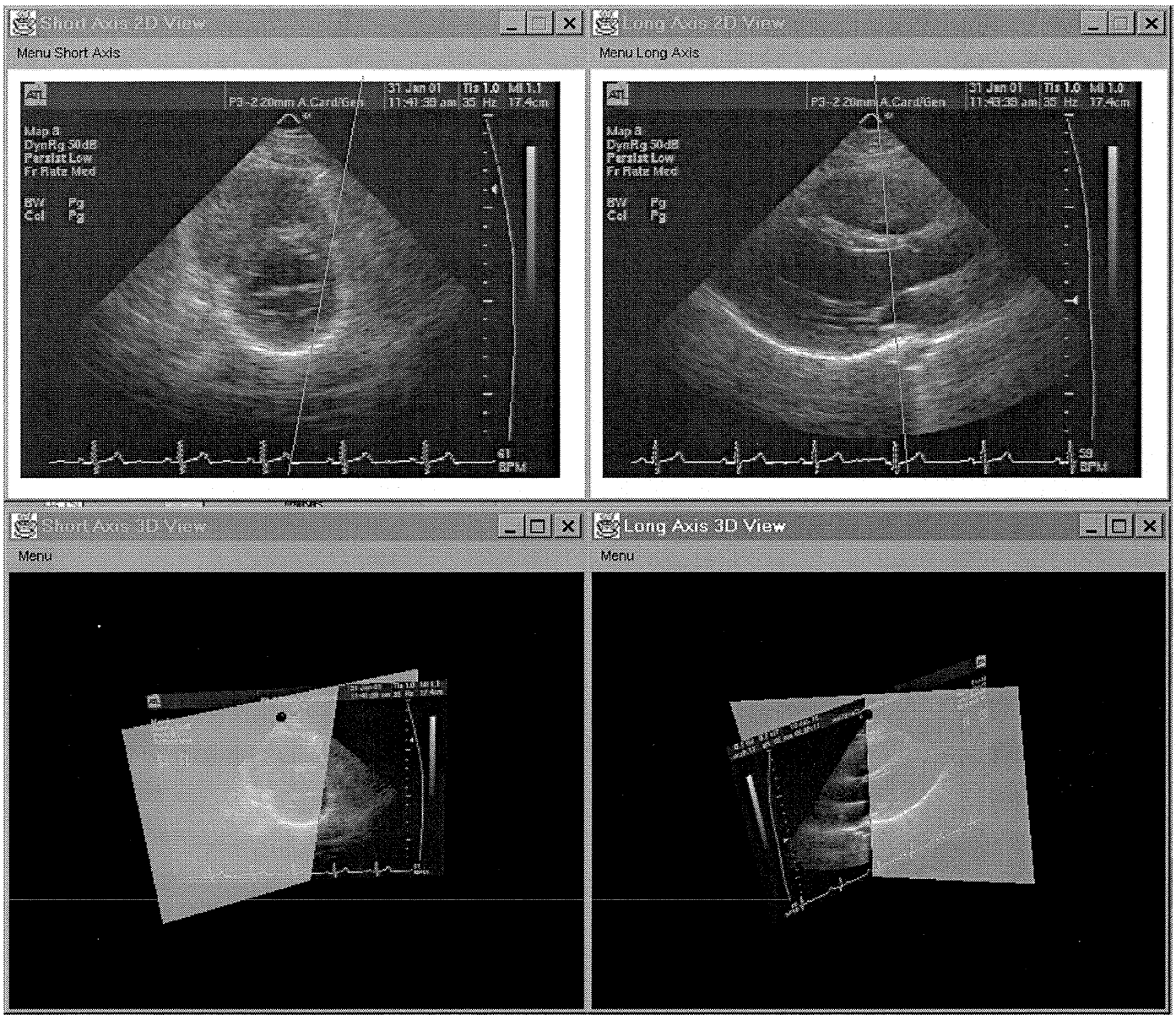

Figure 1. Visual guidance system. Parasternal short axis and long axis scout images of the left ventricle are displayed in the left and right columns. Above, The location of the current image plane is shown as a line of intersection. Below, the current image's location is the semi-transparent plane.



Figure 2. By reconstructing an approximation of the patient's ventricle, the location and orientation of imaging planes can be evaluated anatomically. This was the rationale for visual guidance method #3.

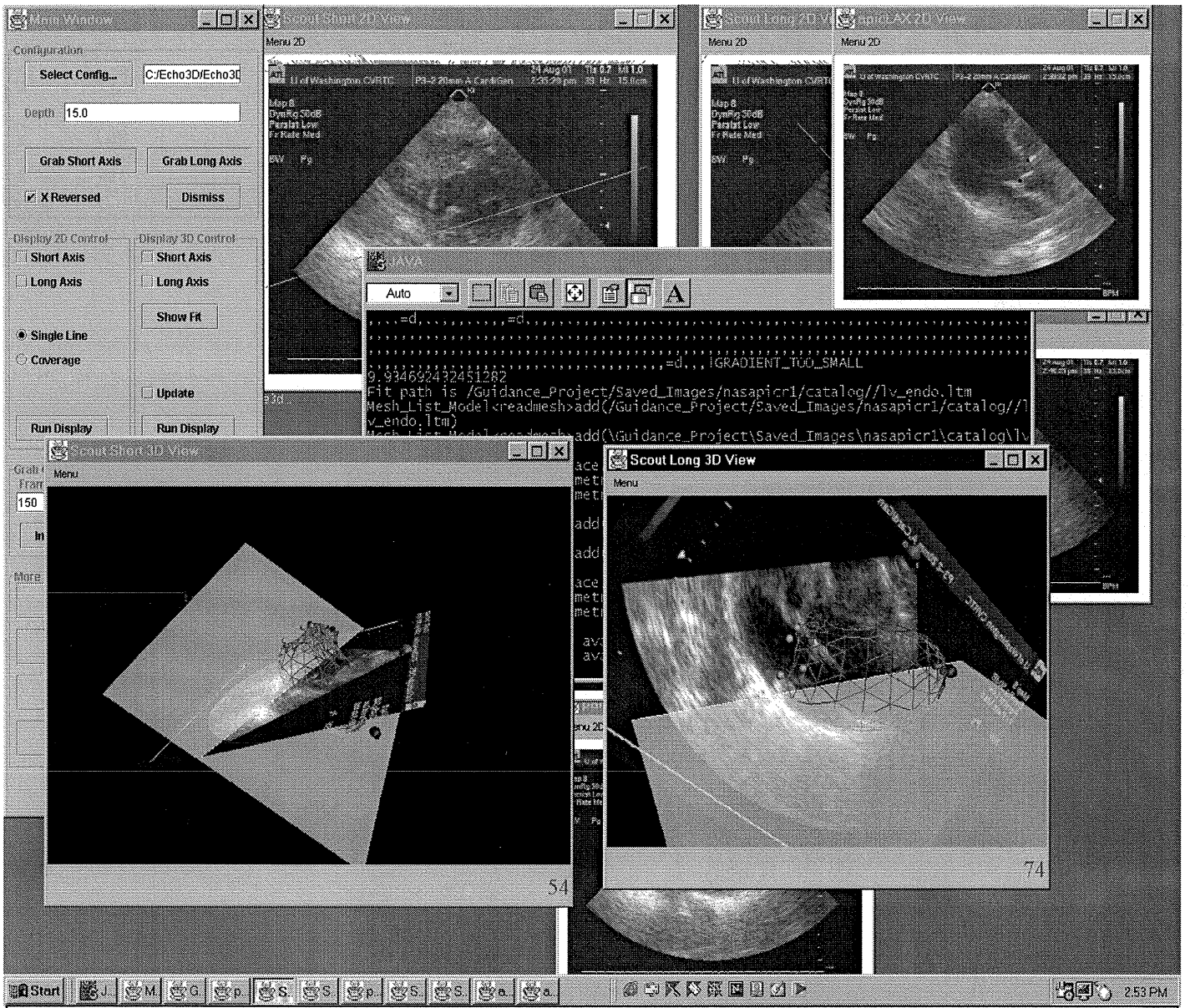

Figure 3. User interface for visual guidance system, with two windows displaying the estimated 3D left ventricular surface as a triangulated mesh to help monitor scanning. The position and orientation of the current image plane (translucent) can be appreciated relative to the anatomy of the heart as represented by the 3D surface, and relative to the scout images (gray scale). The colored spheres are the landmark points traced from the images. The user interface menu is at the upper left; two line of intersection displays are in the top middle and top right windows; and tracing of the aortic valve point is seen in the upper right window. Other visual guidance displays are behind. The text window ("Java") monitors software processing and aids debugging; it is temporary.

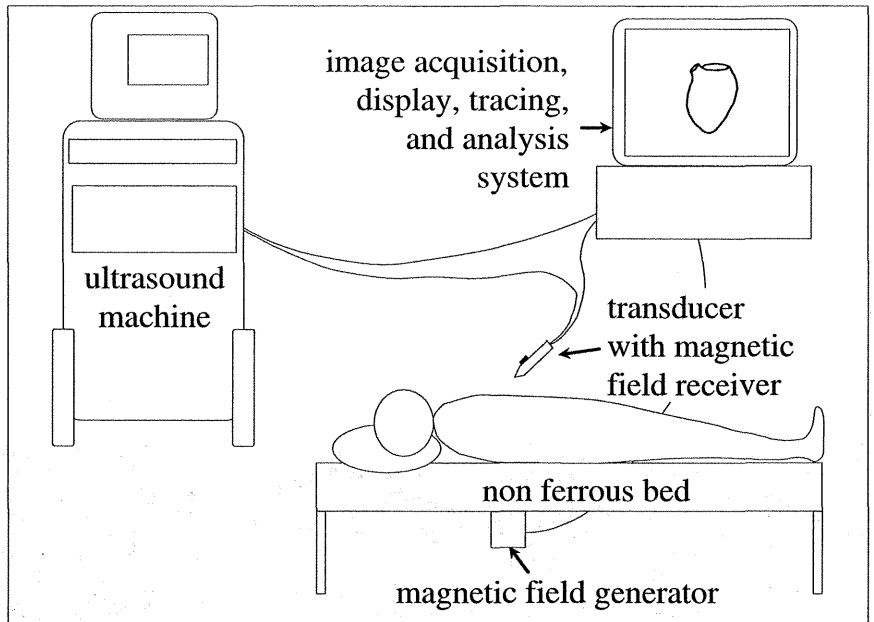

Figure 4. Schematic diagram of 3D echo imaging system

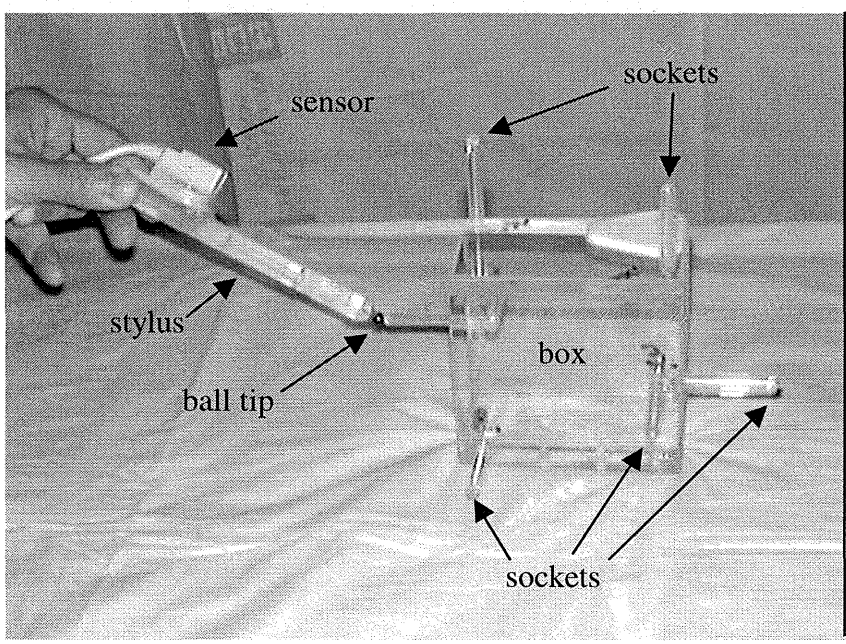

Fig. 5. In vitro system used for testing the precision of the magnetic field system for tracking the position and orientation of the ultrasound transducer. The stylus mimics the transducer. The magnetic field sensor is mounted on the stylus. The stylus is then used to repeatedly locate the x,y,z positions of the sockets.

Table 1. Diagnoses of Catalog Hearts

Diagnosis	Number
Normal	52
Cardiomyopathy	16
Angina	2
Ischemic mitral regurgitation	12
Myocardial infarction	22

Results

#1: Visual Anatomic Guidance System

We implemented all three methods of visual guidance, including the *intersection with 3D surface* (Fig. 3). To enable the SmartFit method we created a catalog of 3D reconstructions of the left ventricle from 3D echo scans. The current catalog contains 52 normal subjects and 52 patients with diverse diagnoses (Table 1), and has been adequate for reconstructing a variety of patients' ventricles. Our catalog for the right ventricle, however, only has 12 studies.

We recruited 30 subjects to evaluate the visual guidance system. However our protocol was very long, since both the sonographer and the inexperienced medicine resident did guided and unguided image acquisitions. Consequently the patient or subject often moved, causing rejection of a large number of studies. We were able to obtain analyzable data in 13 subjects in the left ventricular volume study, and 5 subjects in the right ventricular volume study.

The quantitative analysis of the left ventricle failed to show any benefit of visual guidance. That is, the accuracy and reproducibility of left ventricular volume measurement from 2D images was the same with vs. without guidance. This result is probably because the left ventricle has such a regular shape, particularly in the normal subjects and heart failure patients, that deviations in image plane position did not introduce much error in volume measurement.

We had quite a different result when scanning the right ventricle. We observed that the visual anatomic guidance system's SmartFit surface, the 3D surface estimation used for guidance, already provided a physician untrained in scanning with measurements of right ventricular volume that varied from true by a mean error of only 14.2%; this is comparable to the error of the best published two-dimensional (2D) echo method: 16.3% by biplane pyramidal approximation (5). With calculation of right ventricular volume using our modification of the biplane pyramidal method, the guidance gave our inexperienced physician an error of only 5.0%; this is much smaller than previously published and comparable to those of our experienced, trained sonographer (Table 2). As previously reported, the monoplane ellipsoidal approximation method is subject to very high error; this was confirmed in the present study.

Table 2. Error in Determining Right Ventricular End Diastolic Volume (mean error, presented as % of true volume because the published study was in pediatric patients and the present study was in adults)

		Inexperienced		Sonographer	
Method of Determining Right Ventricular Volume	Published in (5) (N)	Un-guided	Guided	Un-guided	Guided
SmartFit estimated surface			14.2		
Biplane Pyramidal	16.3 (17)	19.7	5.0	2.3	8.8
Biplane Ellipsoid	40.2 (23)				
Biplane Multiple Slice	40.2 (23)				
Monoplane Ellipsoidal	50.0 (33)	63.0	52.5	48.7	57.0
Monoplane Multiple Slice	56.5 (33)				

Furthermore, our experience to date has revealed that the guidance system accelerated the rate at which an untrained medicine resident learned to perform scanning by helping her to relate the image to the anatomy. The heart has a complex 3D structure; learning how to manipulate the transducer, to interpret what one is seeing on the images, and where the desired image planes for standard views are located and oriented can be very confusing to the novice. Another difficulty in cardiac imaging is that the parasternal and apical acoustic windows limit the freedom of the sonographer to search for optimal image quality. Our experienced sonographer found that the guidance system forced her to move the transducer more laterally than expected for the apical views; when displayed relative to the scout images it was obvious that her unguided views tended to be foreshortened. Thus the guidance system is not only an effective teaching tool, but may help improve the performance of sonographers as well.

Aim #2: Tracking the Ultrasound Transducer:

The results in Table 2 show that Internav's immune system was able to track the transducer position accurately, even on the stretcher. Note however that these tests were performed on a static system, i.e., without moving the transducer during tracking.

Table 2. Comparison of Two Magnetic Field Tracking Systems' Precision (RMS)

	Control (mm)*	Stretcher (mm)*
Immune (Internav, Inc.)	0.941, 0.930, 0.909	1.216, 1.205
Flock of Birds (Ascension Technology, Inc.)	0.99, 1.25	4.90, 6.04

* multiple measurements were made at each test condition

Since ultrasound images are acquired during freehand scanning, we also tested the immune system's accuracy during dynamic scanning. Internav developed this capability without additional cost (Table 3). We also found that Internav's immune system allowed us to measure distance between two points with high accuracy (control 10.92 cm, static test on stretcher 10.85 cm, dynamic test on stretcher 10.84 cm).

Table 3. Internav Tracking System Precision (RMS)

	Control (mm)*	Stretcher (mm)*
Static Testing	1.48, 1.75, 0.76	1.18, 1.04
Dynamic Testing	1.79, 1.05	1.24, 0.97

* multiple measurements were made at each test condition

These results demonstrate that Internav Inc.'s immune system allows the ultrasound transducer to be tracked accurately even in the vicinity of ferromagnetic interference such as over a hospital stretcher.

Aim #3: Visual Guidance for the Right Ventricle

The piecewise smooth subdivision method is capable of reconstructing the endocardial surface of the complexly shaped right ventricle. This was demonstrated by the close correlation between 3D echo measurements and true right ventricular volume (3D echo volume =1.2 x true volume, r=0.998, SEE=3.2 ml, $p<0.001$) and mass (3D mass =1.0 x true mass, r=0.996, SEE=4.5 g, p=0.031). In two hearts, the shape of the surface reconstructed from 3D echo data agreed with the surface of a plaster cast of the endocardium: the mean intervening distance was 1.1 +/- 0.0 mm for one and 1.3 +/- 0.0 mm for the other (2). These results indicate that our method is able to reconstruct the right ventricle with shape accuracy in 3D. These results suggest that visual

anatomic guidance using method #3, *intersection with 3D surface*, is feasible for multiple organ systems other than the heart.

Discussion

SIGNIFICANCE OF THIS RESEARCH IN SPACE AND ON EARTH

Benefit to Space Medicine: Our system provides visual anatomic guidance to help flight crewmembers in obtaining images of optimal diagnostic quality (Critical Path Question 11.03, 11.12, 11.22, 11.26, 11.30, and 11.38). This may assist in monitoring the health status of the flight crew over long duration exposure to microgravity, diagnosing medical problems, evaluating the effect of treatment, and collecting scientific data for research. The visual guidance system may also facilitate pre-flight training in ultrasound imaging. Visual anatomic guidance may also provide the tools to support therapeutic interventions in Space, addressing Critical Path Questions 11.02 and 11.12. For example, the guidance system can be upgraded to permit an expert on Earth to give the flight crewmember additional feedback on how to manipulate the ultrasound transducer and where to obtain additional images. Potential flight applications are to assist the diagnosis of in-flight medical problems and emergencies, and to provide guidance for ultrasound-based therapy such as high frequency ultrasound for hemostasis.

Benefit to Patient Care on Earth: The visual guidance system may help sonographers in positioning images in anatomically correct views and/or anatomically reproducible views. By reducing variability in measuring organ dimensions, visual guidance can improve patient care in two ways: a) the measurements made from the echo study will more reliably indicate patient status, and b) serial measurements will more sensitively detect changes in a patient's condition.

Educational Benefits: 3D anatomic guidance can be used to teach sonographers how to manipulate the echo transducer to obtain correct views. 3D guidance can also be used to facilitate the training of cardiology fellows. Training time will be reduced because the guidance system shows trainees in real-time how the image plane changes position and orientation as they manipulate the ultrasound transducer. Indeed we have already found that the visual guidance accelerated a medical resident's acquisition of scanning skills.

Economic Benefits: Guiding the sonographer to the correct views could reduce the time needed to search for these views, thus increasing the echo lab's throughput. Furthermore, the ability to document accuracy in image plane positioning may increase the acceptability of "outside" studies from referring physicians, with concomitant reduction in wasteful duplication of studies by consultants. In telemedicine consultations, the remote expert may utilize our guidance system to assist or direct the person doing the imaging to assist.

Research Benefits: Despite its superior accuracy and reproducibility, 3D echo would be expensive to apply to clinical trials. However the use of 3D anatomic guidance to improve accuracy and reproducibility may enhance the value of 2D echo as either a trial endpoint or descriptive parameter.

Other Information and Materials

Bibliography: no publications or presentations yet, as the data analysis was just completed.

Number of Funded Students:

Pre-college: 0

Undergraduate: 1 (Michal Hubka received salary support)

Graduate: 0

Post-doctoral: 1 (Jennifer Dorosz, MD received technical support)

Flight Hardware / NASA Ground Facilities used for this project: none

Inventions: The methodology for visual guidance as developed for this grant has been disclosed as an invention to the Office of Technology Transfer at the University of Washington. In addition, the concept for expert guidance as proposed for a pending NASA grant, although not reduced to practice, has also been disclosed as an invention. No patent applications have yet been filed. However Internav Inc is preparing a patent filing on its immune magnetic field tracking system in January or February, 2002.

Literature Cited

1. Legget ME, Leotta DF, Bolson EL, McDonald JA, Martin RW, Li X-N, et al. System for quantitative three dimensional echocardiography of the left ventricle based on a magnetic field position and orientation sensing system. IEEE Trans Biomed Eng 1998;45:494-504.

2. Hubka M, Bolson EL, McDonald JA, Martin RW, Munt B, Sheehan FH. Three-dimensional echocardiographic measurement of left and right ventricular mass and volume: In vitro validation. Intl J Card Imag 2001;(in press).

3. Lange PE, Seiffert PA, Pices F, Wersel A, Onnasch DGW, Habne HJ, et al. Value of image enhancement and injection of contrast medium for right ventricular volume determination by two-dimensional echocardiography in congenital heart disease. Am J Cardiol 1985;55:152-157.

4. Levine RA, Gibson TC, Aretz T, Gillam LD, Guyer DE, King ME, et al. Echocardiographic measurement of right ventricular volume. Circulation 1984;69:497-505.

5. Helbing WA, Bosch HG, Maliepaard C, Rebergen SA, van der Geest RJ, Hansen B, et al. Comparison of echocardiographic methods with magnetic resonance imaging for assessment of right ventricular function in children. Am J Cardiol 1995;76:589-594.